

CASE REPORT

Scrotal haematoma following vasectomy: an unusual surgical emergency

Bobby O'Leary^{1,2}

¹Department of Surgery, Midlands Regional Hospital, Laois, Ireland
²Department of Gynaecology, St. Vincent's University Hospital, Dublin, Ireland

Correspondence to
 Dr Bobby O'Leary,
 robertd.oleary@gmail.com

SUMMARY

A 46-year-old man who underwent a vasectomy at his general practitioner presented to the emergency department at a regional hospital with a 6 h history of scrotal swelling and skin discolouration. He was haemodynamically stable on admission, with a large, dark red swelling in his scrotum. The patient was admitted to an acute surgical unit for exploration of his scrotum. Bilateral transverse incisions were made in the patient's groin, and approximately 600 mL of blood was drained from the patient's scrotum. Postoperatively, the patient performed well, and was discharged home on oral antibiotics and analgesia. The patient's scrotum healed well, and after 2 months of follow-up, he was discharged.

BACKGROUND

Vasectomy is seen as a safe and simple procedure by the majority of the public. While this may be true when compared with the gynaecological equivalent, complications from vasectomy still exist and any patient undergoing such a procedure should be well informed before undergoing it.

CASE PRESENTATION

A 46-year-old man presented to the emergency department of a regional hospital at approximately 19:00 with a 6 h history of scrotal swelling and skin discolouration. Earlier that afternoon the man had undergone a vasectomy at his local general practitioner, and later at home had noticed a dark coloured swelling on the right side of his scrotum (figure 1). The patient was able to void freely. His medical history was significant only for hypertension.

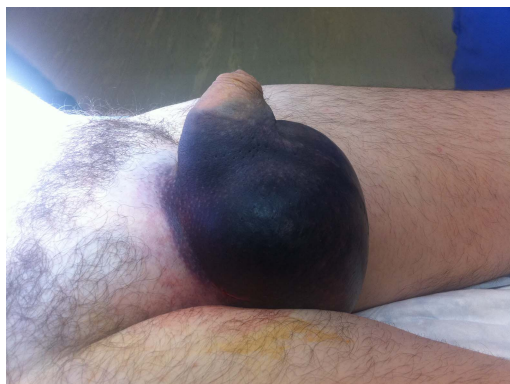


Figure 1 Preoperative image of scrotal swelling and skin discolouration.

On examination, the patient was conscious, coherent and afebrile. He was haemodynamically stable. His vital signs were normal. There was a large non-pulsatile swelling throughout the scrotum which extended superiorly to the right and left groin.

INVESTIGATIONS

Full blood count, renal function tests, coagulation studies and C reactive protein were normal on admission.

DIFFERENTIAL DIAGNOSIS

Our initial diagnosis was a scrotal haematoma secondary to vasectomy.

TREATMENT

The patient was admitted to the surgical ward and was taken to the theatre.

Transverse incisions were made bilaterally at the groin, and approximately 500–600 mL of blood was released from the scrotum (figure 2). Bleeding vessels were secured with diathermy. The vas deferens were identified and double ligated at each end. Haemostasis was achieved and the patient was returned to the ward.

Postoperatively, the patient performed well with intravenous antibiotics, analgesia and a scrotal support. There was some serosanguinous fluid oozing from the incision sites for 2 days, which then subsided completely. He was discharged 4 days postprocedure with oral antibiotics, analgesia and a scrotal support.

OUTCOME AND FOLLOW-UP

The patient was followed up in the outpatient department (OPD) 2 weeks later, and was prescribed analgesia and to continue to use his scrotal support. Two months later, this patient was seen again in the surgical OPD, and given he was without any further surgical concerns; he was discharged back to primary care.

DISCUSSION

Vasectomy remains the world's most common form of permanent male contraception,¹ and has been shown to be a reliable and safe procedure.

The goal of vasectomy is to transect the vas deferens, ensuring that sperm are not present in the patient's ejaculate. The vas deferens is a continuation of the duct of the epididymis, carrying spermatozoa from the testis to the duct of the seminal gland, together forming the ejaculatory duct.



To cite: O'Leary B. *BMJ Case Rep* Published online: [please include Day Month Year] doi:10.1136/bcr-2013-202421

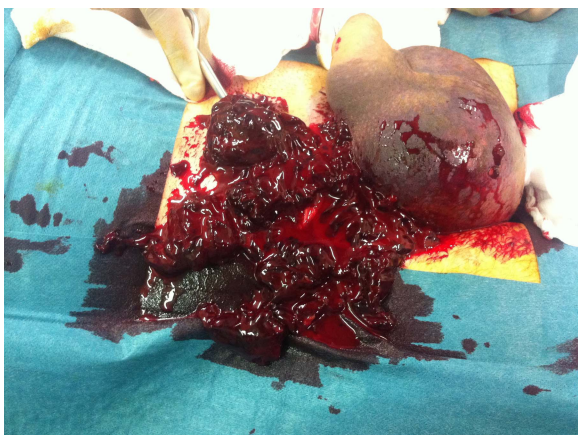

Figure 2 Intraoperative image of scrotal evacuation, showing haematoma with clots.

Interruption of this channel should ensure aspermatozoic ejaculations.

No scalpel vasectomy has become the gold standard worldwide, with strong evidence showing lower rates of all cause morbidity when compared with the traditional incision method.²

While vasectomy has enjoyed a low morbidity rate, there are some important postoperative complications to consider. The most common of these are haematoma, infection, sperm granuloma and postvasectomy pain syndrome. Of these, haematoma is the most common, with an overall rate of postoperative haematoma in the literature of approximately 2% (0.09–29%).^{1 3 4}

The operator experience has been quoted as a key predictor of postoperative complications, with a study showing that operators who performed 50 or more vasectomies per year had a 66% lower complication rate than those who performed 10 or less per year.¹

Documented cases in the literature of scrotal haematoma which are as serious as shown here are scarce. Viddeleer *et al* showed just how serious this simple condition can become, describing a single patient who developed Fournier's gangrene following a vasectomy, and who consequently died.⁵ Other similar cases of postvasectomy Fournier's gangrene have been published in the literature,^{6 7} though to, the best of our knowledge, none have been published within the past 10 years.

Scrotal haematoma is thought to occur most commonly due to damage to the venous structures, most notably the pampiniform

plexus. Given the elasticity of the scrotum and its poor tamponading effects, any bleeding will be afforded ample space to form a haematoma. Exploration and drainage of the scrotum is the only treatment available for large scrotal haematomas which are worsening, or not responding to conservative management.

Learning points

- ▶ Although vasectomy is quite a safe procedure, complications do occur and can need emergent management.
- ▶ Haematoma is the most common postoperative complication, meaning that strict haemostasis is essential at the conclusion of each procedure.
- ▶ Operator experience is a key predictor in postoperative morbidity, with more experienced surgeons having significantly lower complication rates than their counterparts.

Acknowledgements Mr Farrukh Naseem is acknowledged for his assistance with this case report.

Contributors BO reviewed the case notes, formulated the discussion and wrote the case report.

Competing interests None.

Patient consent Obtained.

Provenance and peer review Not commissioned; externally peer reviewed.

REFERENCES

- 1 Kendrick JS, Gonzales B, Huber DH, *et al*. Complications of vasectomies in the United States. *J Fam Pract* 1987;25:245–8.
- 2 Cook LA, Pun A, van Vliet H, *et al*. Scalpel versus no-scalpel incision for vasectomy. *Cochrane Database Syst Rev* 2007;(2):CD004112.
- 3 Awsare NS, Krishnan J, Boustead GB, *et al*. Complications of vasectomy. *Ann R Coll Surg Engl* 2005;87:406–10.
- 4 Adams CE, Wald M. Risks and complications of vasectomy. *Urol Clin North Am* 2009;36:331–6.
- 5 Viddeleer AC, Lycklama à Nijeholt GA. Lethal Fournier's gangrene following vasectomy. *J Urol* 1992;147:1613–14.
- 6 Patel A, Ramsay JW, Whitfield HN. Fournier's gangrene of the scrotum following day case vasectomy. *J R Soc Med* 1991;84:49–50.
- 7 Chantarasak ND, Basu PK. Fournier's gangrene following vasectomy. *Br J Urol* 1988;61:538–9.

Copyright 2014 BMJ Publishing Group. All rights reserved. For permission to reuse any of this content visit <http://group.bmj.com/group/rights-licensing/permissions>.
BMJ Case Report Fellows may re-use this article for personal use and teaching without any further permission.

Become a Fellow of BMJ Case Reports today and you can:

- ▶ Submit as many cases as you like
- ▶ Enjoy fast sympathetic peer review and rapid publication of accepted articles
- ▶ Access all the published articles
- ▶ Re-use any of the published material for personal use and teaching without further permission

For information on Institutional Fellowships contact consortiasales@bmjgroup.com

Visit casereports.bmj.com for more articles like this and to become a Fellow