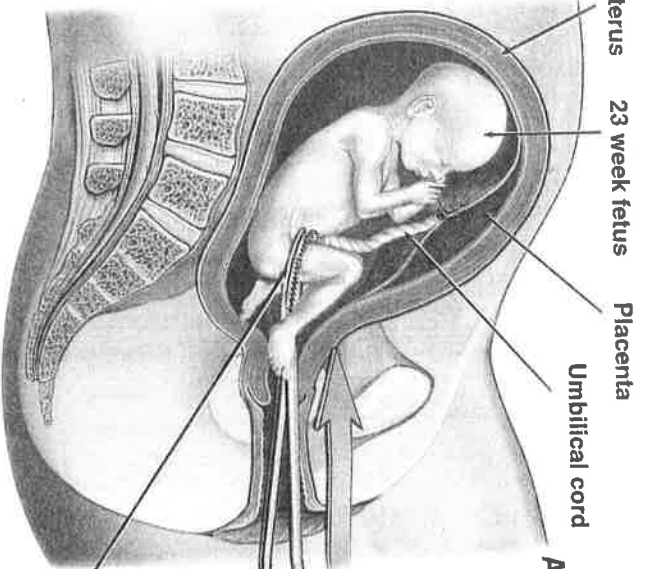
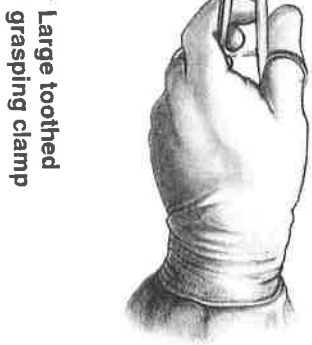

Dilation and Evacuation Abortion (D&E) of a 23 Week Old Fetus

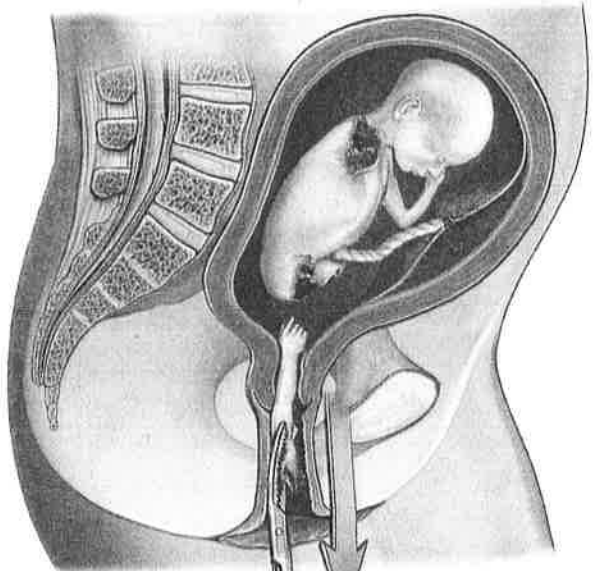


A. The body parts are grasped at random with a long toothed clamp.



Large toothed grasping clamp

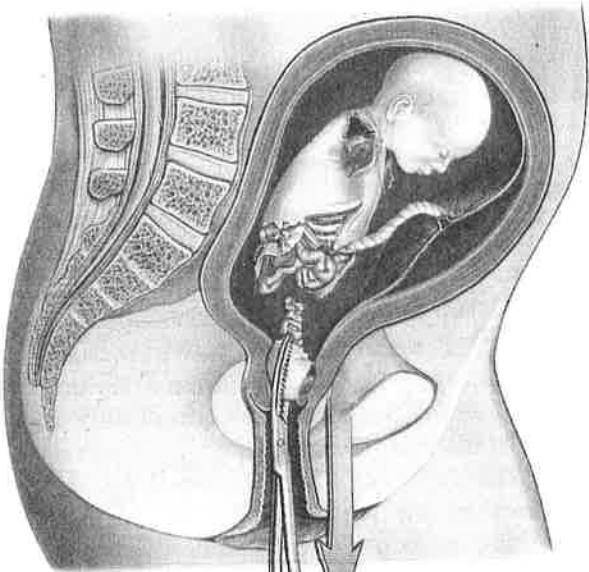
Cut-away view of mother's pelvis



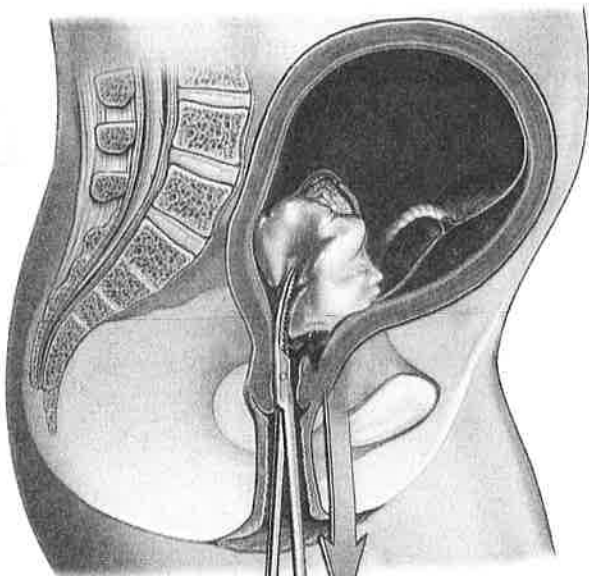
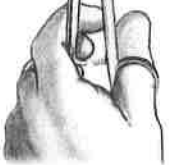
B. The body parts are pulled from the fetal body out the vaginal canal.



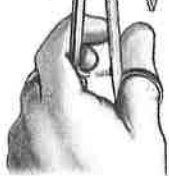
70mm fetal forearm



C. The remaining body parts are grasped and pulled out.



D. The head is grasped and crushed in order to remove it from the vaginal canal.



E. The placenta and remaining contents are suctioned from the uterus.